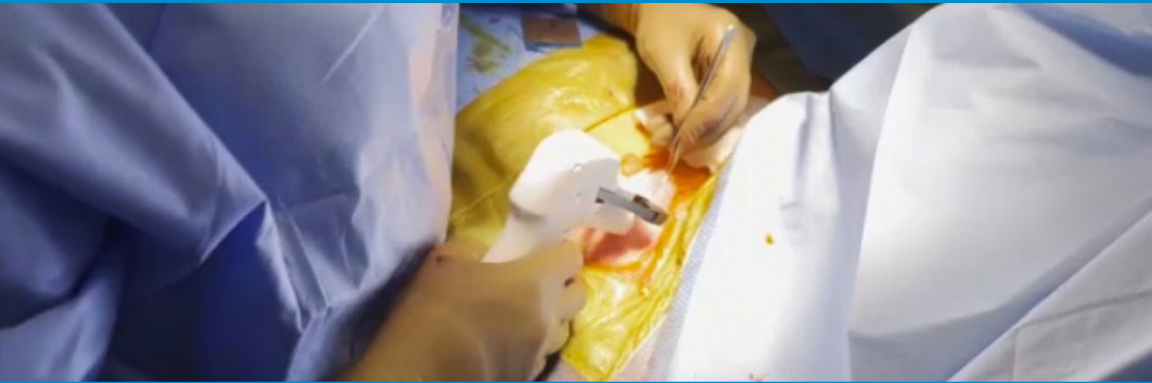

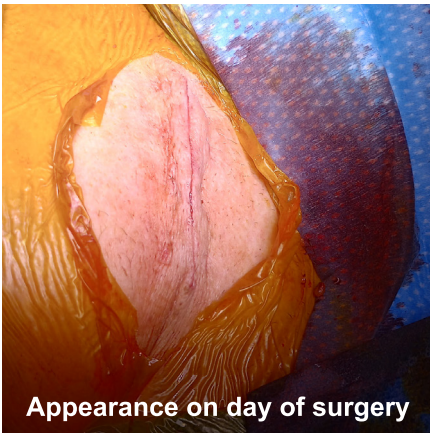
### SubQ It! for Closing Pacemaker Incisions



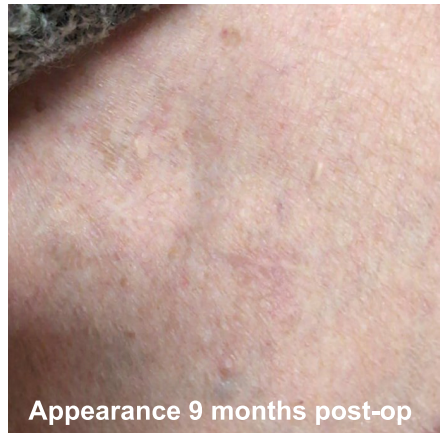**Background:** 74 year-old female, 160cm, 67.1 kg, with paroxysmal AV block and baseline left bundle branch block s/p implantation of a comprehensive conduction system pacing (Atrial lead in the Bachmann bundle, ventricular lead in the left bundle branch area).

**Closing Incision:** The incision was closed with 3 sub-epidermal interrupted 2-0 Monocryl sutures and then 8 SubQ It! Sutures to complete subcutaneous approximation of the skin edges. Dermabond adhesive was applied subsequently.

**Total time spent closing the incision was approximately 5 minutes.**



Appearance on day of surgery



Appearance 9 months post-op

Case provided by Dr. Daniel Lustgarten, University of Vermont Medical Center

#### SubQ It! ordering information

REF 412010 SubQ It! Model SU-10 with 10 dermal fasteners  
 REF 422025 SubQ It! Model SU-25 with 25 dermal fasteners

Each model sold in boxes of 10 sterile, single use devices

OPUS KSD, Inc. | 50 Corporate Park Dr., Suite 710, Pembroke, MA 02359 | Telephone: (339) 933-8811