

## Assessment of a Novel Subcutaneous, Bioabsorbable Skin Closure System<sup>1,2</sup>


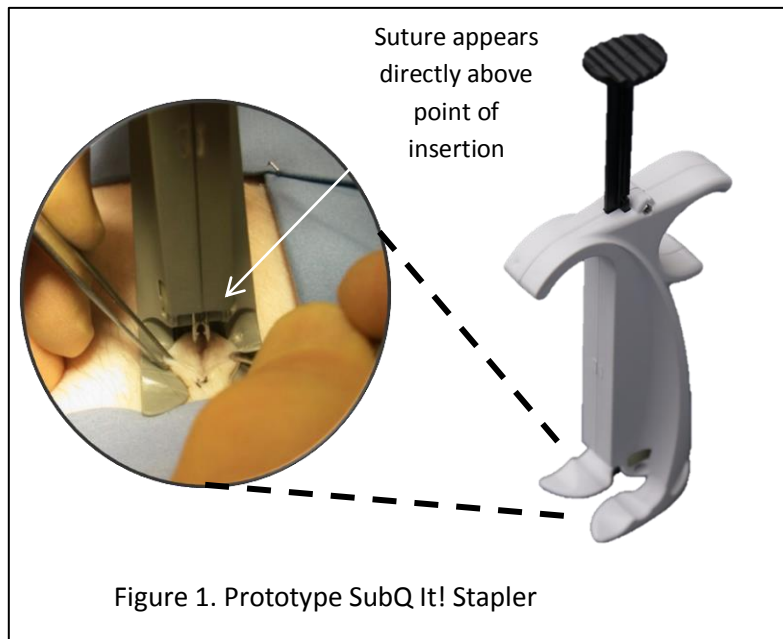
Authors: <sup>1</sup>Kenneth S Danielson, MD, <sup>1</sup>Charles H Rogers, PhD, <sup>2</sup>Karen A Moodie, MS, DVM, Vicki J. Scheidt, DVM, DAVD, <sup>2</sup>Susan A Kane, CVT, <sup>2</sup>Rendall R Strawbridge, BS, <sup>2,3</sup>P. Jack Hoopes, DVM, PhD

<sup>1</sup> OPUS KSD Inc. <sup>2</sup> Department of Surgery, Geisel School of Medicine at Dartmouth <sup>3</sup> Thayer School of Engineering, Dartmouth College

**Objective:** The goal of this study is to assess the cosmetic, functional and tensile strength parameters of a novel, stapler-based subcutaneous bioabsorbable skin closure system, in a porcine model.

**Description and Method of Use:** A disposable stapler system, preloaded with uniquely shaped bioabsorbable staples, has been developed to close various length skin incisions, including laparoscopic incisions. The "SubQ It!" stapler exploits a design geometry chosen to permit excellent visibility for the surgeon to precisely control placement of the staple, especially important in closing small 7-10 mm incisions. Once the surgeon positions the two sides of the tissue in the foot of the stapler, pressing the plunger delivers a staple which has two barbed legs connected by a flexible "bridge". The barbs engage and the bridge holds the two tissue edges together with excellent tensile strength and security. The resulting level of tissue edge apposition and eversion is designed to permit excellent first intention healing.

**Animal Study:** The SubQ It! skin closure system was assessed in seven (7) domestic swine (35-40 kg) using a published and standardized porcine skin incision wound healing model. All animal and procedural activities



<sup>1</sup> Presented 4/20/2013 Emerging Technology Session, SAGES 2013 annual meeting, Baltimore, MD. For further information contact: Kenneth S. Danielson, MD, kensigd@gmail.com, or visit website: [www.subq-it.com](http://www.subq-it.com)

<sup>2</sup> Research reported in this publication was supported by the National Center for Advancing Translational Sciences of the National Institutes of Health under Award Number R43TR000178. The content is solely the responsibility of the authors and does not necessarily represent the official views of the National Institutes of Health



Figure 4 shows the results of examining the 7 cm incision sites using visual inspection and manual palpation for Control (INSORB) and Test (SubQ It!) devices. Both Wound Description assessments (erythema, swelling, gaping, along with manual palpation of the incisions for nodules) and Cosmetic Appearance (scoring for borders, contour, margins, edges and distortion of the incision) using the Hollander Wound Evaluation Scale (HWES) showed no significant difference between Test and Control devices.

Figure 5 shows cosmetic evaluation (wound borders, contour, margins, edges and distortion) of photographs indicating good cosmetic healing in both Test and Control incisions. Incisions on days 3, 7, 10, 60 and 90 exhibited some degree of either edge inversion or margin separation, which decreased the total cosmetic score in both Test and Control groups. Day 3 and 7 incisions closed with the Test device achieved slightly better scores than the Control device but these would not be clinically significant.

Figure 6 shows the total scores combining acute inflammatory reaction, tissue edema hemorrhage, necrosis, new vessels, granulation tissue formation, persistent inflammation and fibrosis. Individually and combined, there was no significant difference between Test and Control devices.

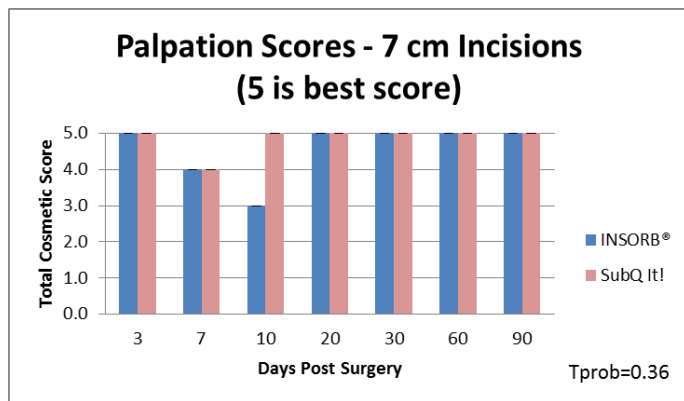


Figure 4. Hollander scores for the Control and the Test incisions based on manual palpation

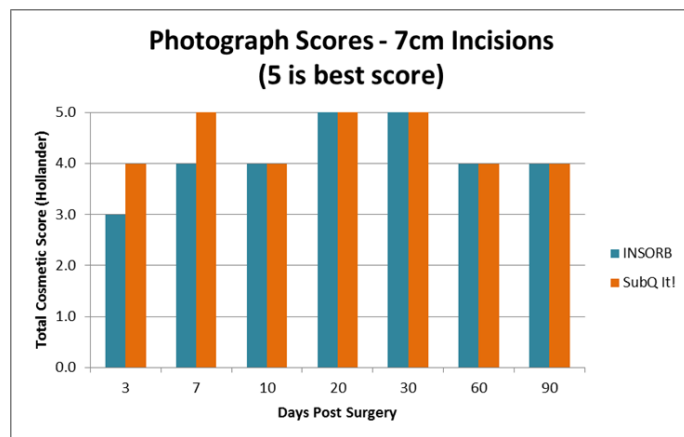


Figure 5. Hollander scores for the Control and the Test incisions based on photographs

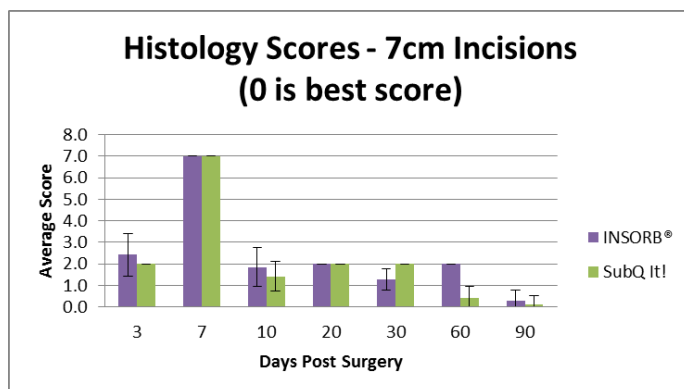


Figure 6. Total scores from histopathology evaluations of H&E sections

As part of the FDA recommended protocol, incisions in which the SubQ It! fastener was removed/replaced were compared to incisions without such intervention. For comparison four (4) incisions, two with intervention and two without, each 2 cm long were compared on each animal (28 incisions total). Figure 7 demonstrates the clinical evaluation using visual and manual palpation of the incisions blinded as to intervention. The “No Intervention” group did not have a staple removed. The “Remove/Replace” group had one staple removed /replaced per incision at the time of surgical closure. There were no differences noted and all wounds demonstrated optimal healing.

Figure 8 shows the evaluation of photographs of the wounds with and without the staple removal procedure. No significant difference was seen in the HWES scores ( $p = 0.60$ ).

Figure 9 shows the results of histopathology evaluation of the 2cm incisions with and without fastener removal. All readings were blinded as to the intervention and duration of healing. Scores shown are totals of individual readings of acute inflammatory reaction, tissue edema hemorrhage, necrosis, new vessels, granulation tissue formation, persistent inflammation and fibrosis, where 0 is the absence of such characteristics. There is a slight increase in scores for the group which had a fastener removed and replaced, as might be expected as this is one of two fasteners in a very small incision. The difference was not significant ( $p = 0.22$ ).

**Conclusions:** Satisfactory wound closures were obtained for the new device on all sized incisions tested. SubQ It! stapler performance was substantially equivalent on 7 cm incisions in all respects to the control device.

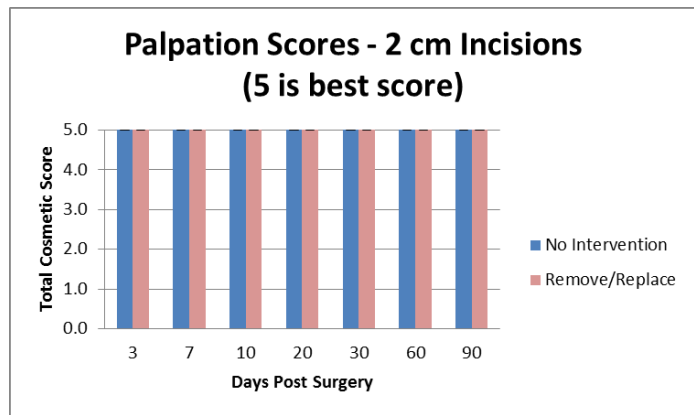


Figure 7. Hollander scores for the 2cm incisions where fastener has been removed and replaced

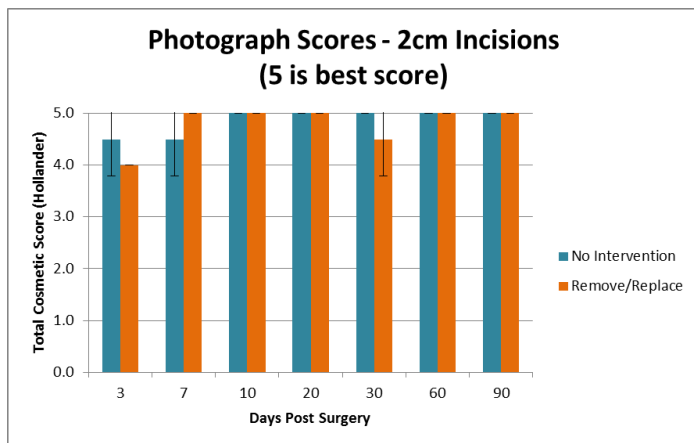


Figure 8. Photographic evaluation of 2cm incisions where fastener has been removed and replaced

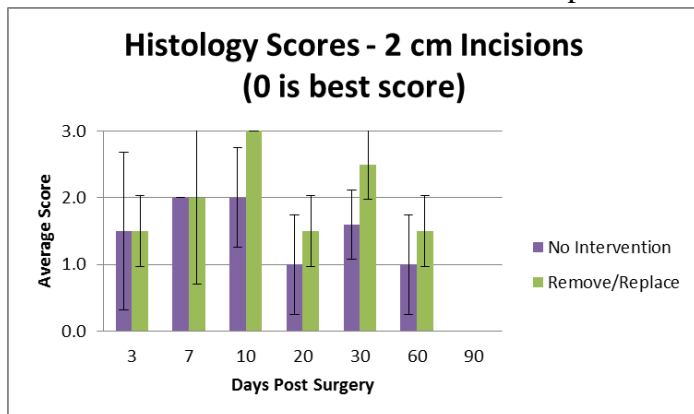


Figure 9. Total scores from histopathology evaluations of 2cm incisions with fastener removal/replaced